

Copyright © McGraw-Hill Education. Permission is granted to reproduce in any form.

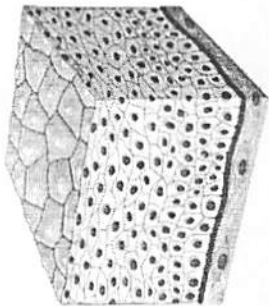
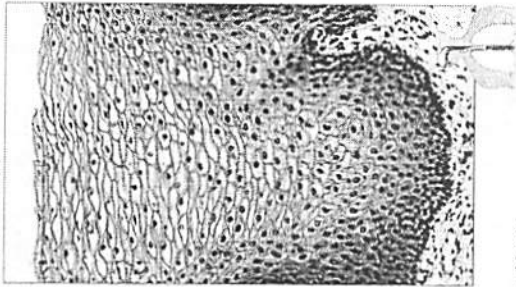


Figure 31.10 McGraw-Hill Education All in One, 6th Edition, © 2012

Copyright © McGraw-Hill Education. Permission is granted to reproduce in any form.

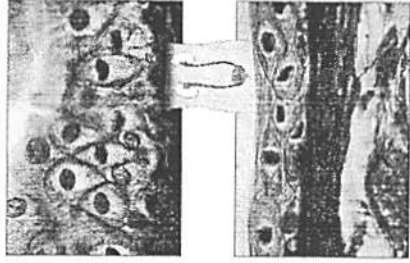
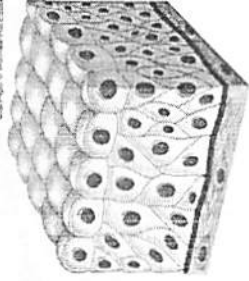


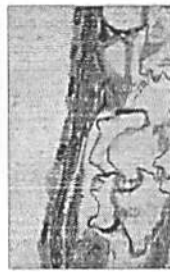Figure 31.11 McGraw-Hill Education All in One, 6th Edition, © 2012

Copyright © McGraw-Hill Education. Permission is granted to reproduce in any form.


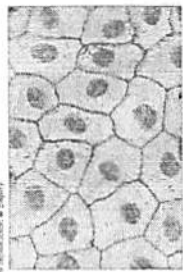
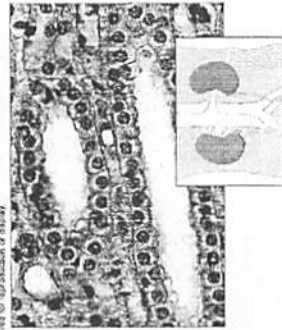


Figure 31.12 McGraw-Hill Education All in One, 6th Edition, © 2012

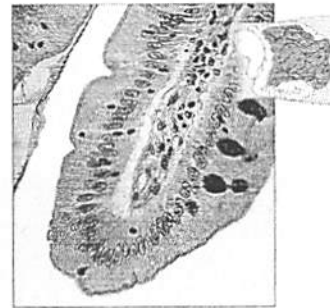Copyright © McGraw-Hill Education. Permission is granted for reproduction or display.



Copyright © McGraw-Hill Education. Permission is granted for reproduction or display.

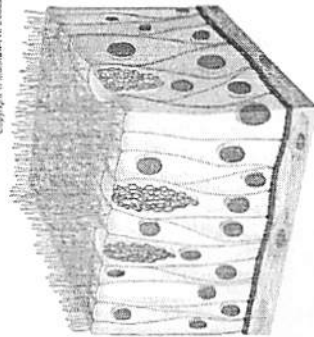


Copyright © McGraw-Hill Education. Permission is granted for reproduction or display.




Copyright © McGraw-Hill Education. Permission is granted for reproduction or display.


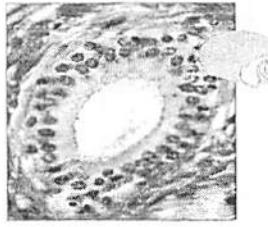
Copyright © McGraw-Hill Education. Permission is granted for reproduction or display.



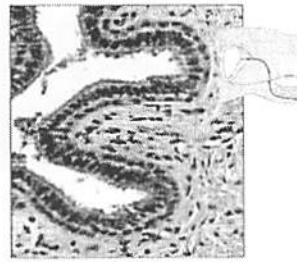
Copyright © McGraw-Hill Education. Permission is granted for reproduction or display.



Copyright © McGraw-Hill Education. Permission is granted for reproduction or display.



Copyright © McGraw-Hill Education. Permission is granted for reproduction or display.



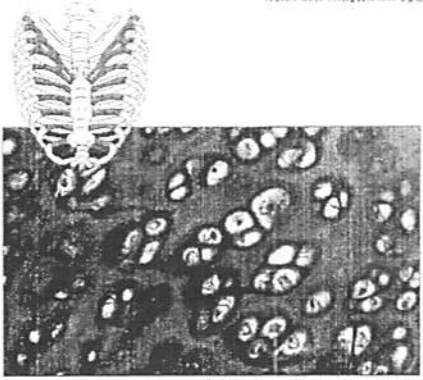
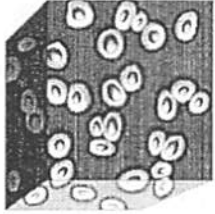


Figure 3: Micrograph of a vertebral body showing trabeculae and osteons.



Copyright © McGraw-Hill Education. Permission is granted for reproduction or display.

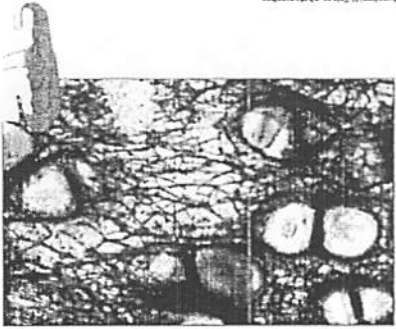


Figure 4: Micrograph of a vertebral body showing trabeculae and osteons.





Figure 5: Micrograph of a vertebral body showing trabeculae and osteons.



Copyright © McGraw-Hill Education. Permission is granted for reproduction or display.


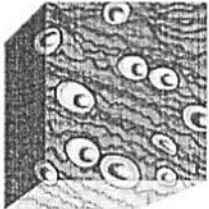



Figure 6: Micrograph of a vertebral body showing trabeculae and osteons.



Copyright © McGraw-Hill Education. Permission is granted for reproduction or display.

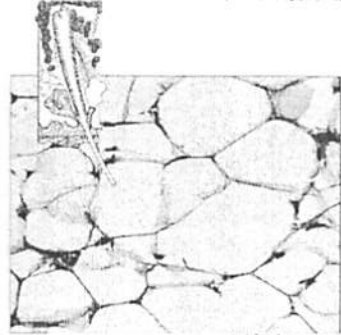
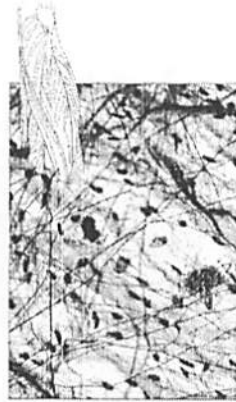
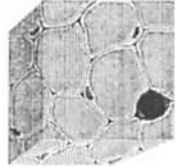
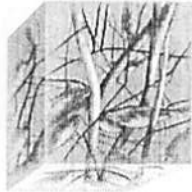

Figure 7: Micrograph of a vertebral body showing trabeculae and osteons.



Copyright © McGraw-Hill Education. Permission is granted for reproduction or display.



Copyright © McGraw-Hill Education. Permission is required for reproduction or display.





Figure 35 McGraw-Hill Education. Permission is required for reproduction or display.

Copyright © McGraw-Hill Education. Permission is required for reproduction or display.

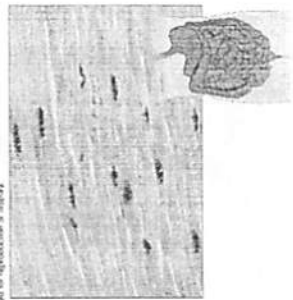


Figure 36 McGraw-Hill Education. Permission is required for reproduction or display.

Copyright © McGraw-Hill Education. Permission is required for reproduction or display.

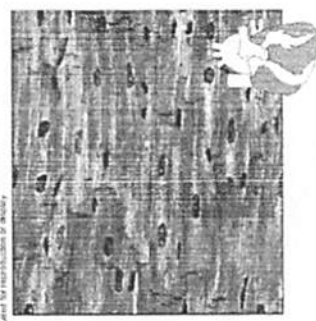


Figure 37 McGraw-Hill Education. Permission is required for reproduction or display.

Copyright © McGraw-Hill Education. Permission is required for reproduction or display.


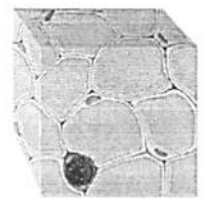


Figure 38 McGraw-Hill Education. Permission is required for reproduction or display.

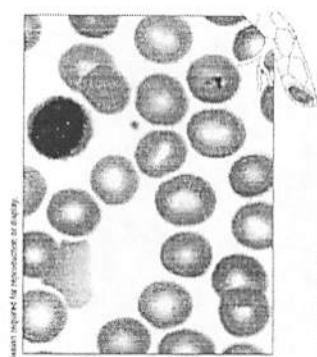
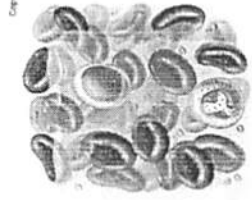


Figure 39 McGraw-Hill Education. Permission is required for reproduction or display.

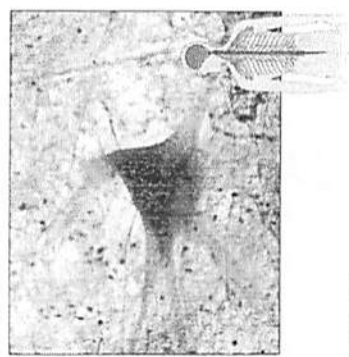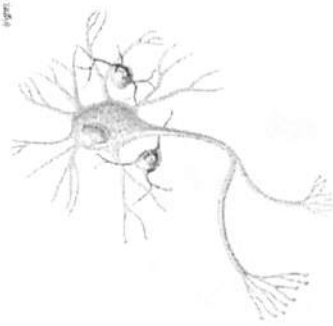


Figure 40 McGraw-Hill Education. Permission is required for reproduction or display.